

LESION STERILIZATION AND TISSUE REPAIR OF LATERALLY LUXATED PRIMARY MANDIBULAR INCISOR: A CASE REPORT

Ibrahim DFA¹, Hussein AS², and Hamzah SH².

¹Faculty of Dentistry, Universiti Teknologi MARA, Sungai Buloh Campus, 47000 Selangor, Malaysia

²Centre of Paediatric Dentistry and Orthodontics Studies, Faculty of Dentistry, Universiti Teknologi MARA, Sungai Buloh Campus, 47000 Selangor, Malaysia

Correspondence:

Alaa Sabah Hussein,
Centre of Paediatric Dentistry and Orthodontics Studies,
Faculty of Dentistry,
Universiti Teknologi MARA,
Sungai Buloh Campus,
47000 Selangor, Malaysia
Email: dr_alaasabah@yahoo.com

Abstract

Lateral luxation injuries are common during childhood and in young adolescence. These injuries involve the surrounding tissues that could lead to extensive clinical treatment problems with a risk of pulpal complications such as pulp necrosis. A case of a healthy 4-year-old Malay boy visiting the paediatric dental clinic after seven months of laterally luxated injury on the lower right lateral incisor (tooth 82) was reported. The traumatic tooth was splinted by a private practitioner three days after the trauma, however, the splint dislodged less than 24-hour after placement. In view of the mother's fear of bringing her child to the dentist due to the COVID-19, no follow-up and further treatment were carried out. This has resulted in the development of discolouration and pulpal necrosis to the injured tooth. Lesion sterilization and tissue repair technique (LSTR) was performed. This report highlights the rare occurrence of lateral luxation injury on tooth 82 and the management of pulp necrosis as a complication via lesion sterilization and tissue repair technique due to the uncooperative behaviour of the child.

Keywords: Lateral Luxation, Lesion Sterilization and Tissue Repair, Primary Teeth, Repositioning and Splinting, Pulp Necrosis

Introduction

Dental trauma is a challenging worldwide public health problem due to its high prevalence and its negative impact on a person's quality of life (1, 2). Traumatic dental injuries often occur in preschool, school-aged children, and young adults leading to treatment requirement in 5% of all injuries (1). The incidence of traumatic injury to the primary dentition is high in a growing child between the ages of one to four years old (3, 4) in view of underdeveloped motor coordination (2). Among the various primary teeth injuries, luxation injuries are common in the primary teeth, amounting to a total of 29.5-57% of all dental injuries (3, 4). Primary maxillary central incisors are the most common (61%), followed by maxillary lateral incisors (19%), mandibular central incisors (8%), and lateral incisors (5%) (5). Lateral luxation is described as tooth displacement towards a direction different from the axial direction (6). The alveolar process is fractured due to the injury and as a result, the tooth becomes immobile (7). According to the guidelines published by the International Association of Dental Traumatology (IADT) 2020, the management of

lateral luxation injuries vary depending on the severity of the insult. The management includes self-repositioning of the tooth, repositioning and splinting or extraction (7).

Delayed repositioning of the laterally luxated teeth may affect the prognosis of the injured tooth. This could happen due to the mechanical damage of the periodontal ligament resulting in cellular necrosis that consequently alters normal haemostasis mechanisms (8). In the case of extensive apical blood supply to the luxation injuries, pulp healing may be jeopardised resulting in pulp necrosis (9).

Pulpal necrosis is manageable using lesion sterilization and tissue repair (LSTR) therapy in which it allows disinfection of the dentinal, pulpal, and periradicular lesions with a combination of antibacterial drugs (10). This endodontic treatment has been proposed as an alternative to the routine pulpectomies in uncooperative children (10, 11).

This case report illustrates a rare occurrence of lateral luxation injuries on the primary mandibular incisor (tooth 82) and the management of pulp necrosis following trauma using LSTR in an uncooperative child. To our knowledge,

this is the first case report of lateral luxation injuries on an uncommon tooth reported in literature.

Case report

A 4-year-old healthy Malay male patient presented to the Paediatric Dental clinic for a dental review of a traumatic tooth. The injury occurred almost seven months prior to the time of initial presentation at our clinic. The patient sustained a traumatic injury at the lower front tooth in which the tooth was labially displaced causing derangement of the occlusion (Figure 1A). The mother reported that he was playing with his sister, when an accident occurred as his sister hit his face. Also, she stated that there was no history of loss of consciousness and the injury was confined to the intraoral region only. The patient had a history of repositioning and splinting by a private dental practitioner three days after the occurrence of the trauma at the end of February 2020 (Figure 1B). The mother stated that the wire dislodged less than 24 hours after teeth repositioning and she failed to seek dental review and follow-up due to fear of COVID-19 and Malaysia's lockdown regulations. The patient reported to our clinic in September 2020 with concerns regarding grey discoloration on the traumatised tooth, seeking/requesting further review. He was healthy with no history of allergies to any drugs and foods, and the medical history was non-contributory. Extraoral examination disclosed no abnormalities. The patient's height and weight were within the normal range for his age. Intraoral examination revealed a dark grey discoloration of the lower right lateral primary incisor (tooth 82) (Figure 2A-D). The tooth was not tender on percussion and no mobility was detected. However, there was a presence of sinus tract (Figure 2D). The rest of the teeth were sound. The eruption and occlusion of the dentition were within a normal range for his age. Intraoral periapical (IOPA) radiographs showed no signs of root fracture or alveolar bone fracture, no periapical radiolucency, and no signs of resorption of the root (Figure 2E). However, increased periodontal ligament space was visible. Underlying permanent tooth germ was intact radiographically and away from the root of tooth 82. After a thorough examination, the case was diagnosed as

lateral luxation with pulp necrosis as a result of the injury. The planned treatment was pulpectomy in accordance with the 2021 American Academy of Paediatric Dentistry (AAPD) Guidelines and 2020 International Association of Dental Traumatology (IADT) Guidelines. Written consent was obtained from the mother for the agreed dental treatment options and the use of both records and photographs for publication purposes. However, pulpectomy procedure was changed to LSTR, which was performed using physical restraint due to anxious and uncooperative behaviour towards the pulpectomy procedure (Figure 3A and B). The access cavity was prepared using round bur. After opening the pulpal chamber of the necrotic tooth, the canal orifice was prepared 2 mm deep and 1 mm wide to create medication receptacles. A rubber dam was used and secured only with wedjets stabilising cord. Pulp chamber was irrigated using saline and 1% sodium hypochlorite. For the preparation of 3-mix paste of antibiotic, ciprofloxacin (200 mg), metronidazole (400 mg), and amoxicillin (500 mg) were pulverized into powder after the removal of the enteric coating on the drugs. The preparation was done similar to the procedure mentioned by Takushige et al. (12). These powdered drugs were then mixed in a ratio of 1:3:3 with propylene glycol to form a 3-mix paste. The 3-mix paste was then placed on the canal orifices, the pulp chamber was then sealed with glass-ionomer cement and further reinforced by composite resin.

Clinical follow-up at one month showed the tooth was asymptomatic with an absence of pain (Figure 4A and B) and radiographically no sign of root resorption (Figure 4C). However, at 4, 9, and 12 months of clinical follow-up, the asymptomatic tooth displayed more greyish colour (Figure 4D, E, G, and H) and the IOPA radiograph showed no sign of root resorption (Figure 4F and I). Subsequent follow-ups were expected to continue until the eruption of its successor. The mother was informed regarding the potential consequences of the permanent successor tooth and the importance of regular follow-ups as well as preventative measures such as oral hygiene care and topical fluoride application.

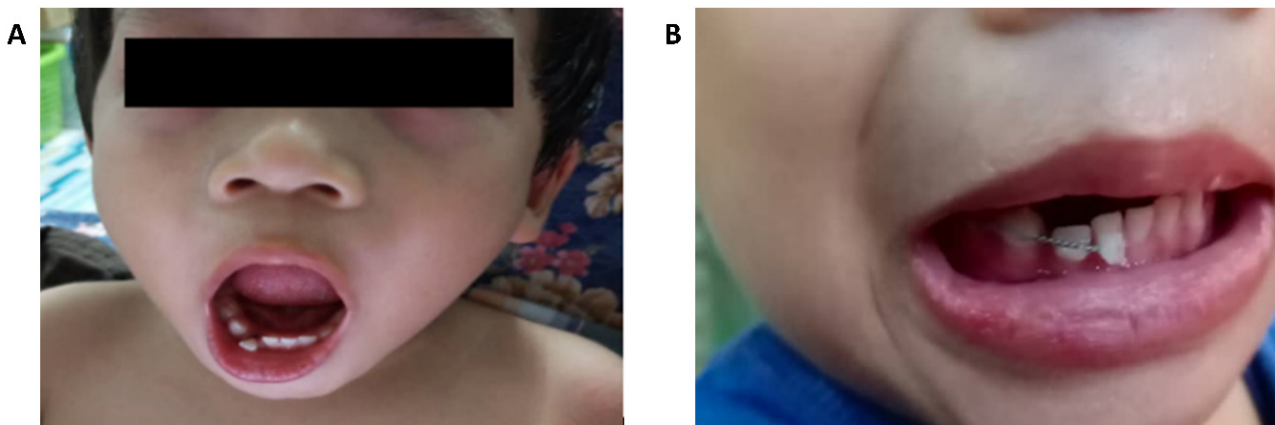

Figure 1: (A) Lateral luxation of tooth 82 which was displaced labially. (B) The tooth was secured with a wire splint

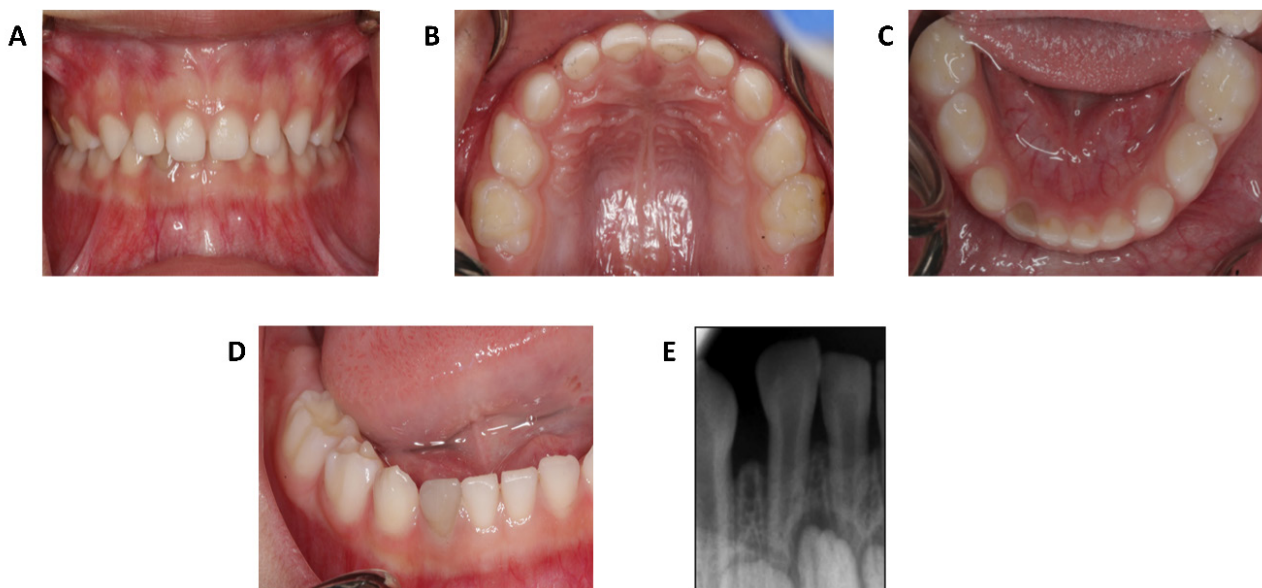


Figure 2: Intraoral photograph showing (A) good interdigitation between maxilla and mandibular dentition; (B) occlusal view of the maxilla; (C) occlusal view of mandible and grey discoloration of the lingual surface of tooth 82; (D) dark grey discoloration of tooth 82 with sinus on the labial site of the gingiva; (E) preoperative periapical radiograph of tooth 82

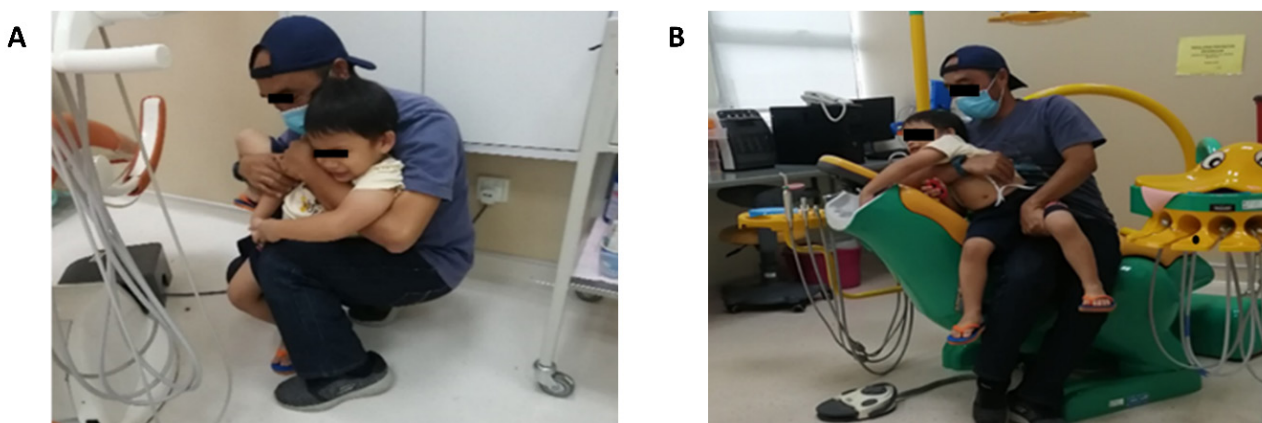


Figure 3: (A & B) Uncooperative behaviour of the child

Discussion

The maxillary central incisors are the most common teeth affected by trauma followed by the maxillary lateral incisors. The percentage of mandibular incisors on the other hand was low (13). In this study, tooth 82 was the only tooth affected by trauma, which is a rare incidence based on literature.

According to the 2020 IADT Guidelines (7), in a situation of severe displacement, lateral luxation injuries are usually managed by repositioning of the tooth gently to its original position. If the injured tooth is unstable in its new position, a flexible splint is indicated for 4 weeks (7). Stabilisation of the injured tooth using the adjacent sound teeth as an anchor is essential for support while allowing the injured tooth to be exposed to the physiological forces

in the oral environment (14). The child’s parent opted for the conservative management of observation after dislodgement of the splint after placement. This decision was made due to COVID-19 regulations during lockdown, hence the child had to bear impact on the prognosis of the injured teeth, which is pulpal necrosis. The repositioned injured tooth was minimally displaced labially. A clinical follow-up 7 months after the post-traumatic injury revealed that the tooth had returned to its original position.

In the case of delayed repositioning, as presented in this study (more than 24 hours after injury), the integrity of the periodontal ligament and neurovascular supply may be compromised, hence affecting the outcome of the tooth and its supporting tissue. Repositioning imposes a risk of periapical inflammation, which could potentially damage the permanent successors. Therefore, dental practitioners

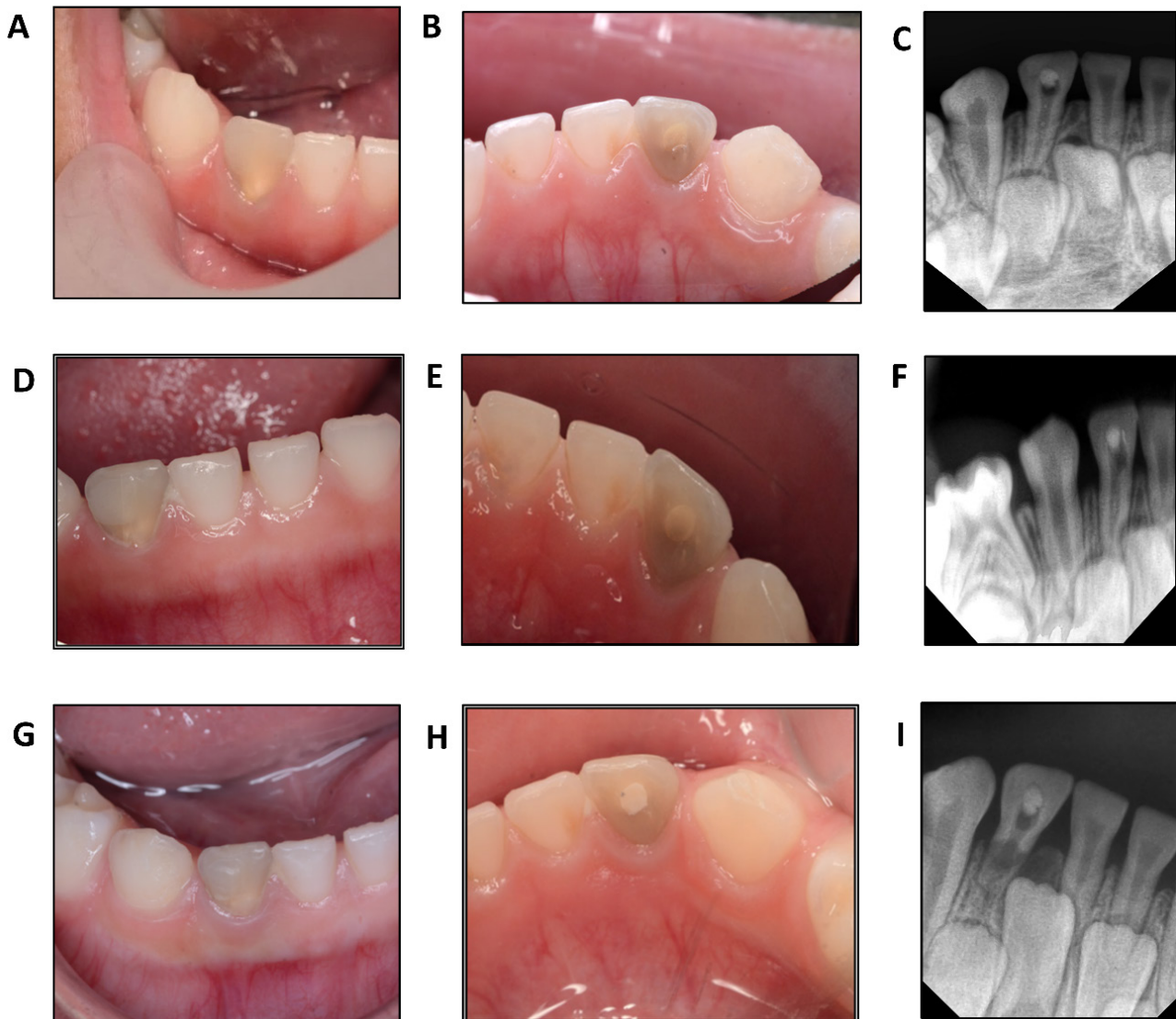


Figure 4: (A) Post LSTR on the labial site of tooth 82 after 1 month. (B) Post LSTR on the lingual site of tooth 82 after 1 month. (C) Post radiograph LSTR on tooth 82 after 1 months. (D) Post LSTR on the labial site of tooth 82 after 4 months. (E) Post LSTR on the lingual site of tooth 82 after 4 months. (F) Post radiograph LSTR on tooth 82 after 4 months. (G) Post LSTR on the labial site of tooth 82 after 9 months. (H) Post LSTR on the lingual site of tooth 82 after 9 months. (I) Post radiograph LSTR on tooth 82 after 9 months

have to carefully consider the requirements necessary for repositioning due to this factor (15).

The sequelae of various long-term complications associated with lateral luxation injury, such as tooth discolouration, pulpal necrosis, pulp canal obliteration, infection-related resorption, ankylosis, and premature tooth loss due to damage to the permanent successor need to be considered (12, 15, 16). In this study, the patient experienced pulpal necrosis. It is well established that the aetiology of pulpal necrosis is due to the ingress of bacteria into the pulp via exposed dentinal tubules of interrupted vascular supply to the pulp (17). An impact to the luxated injury may impede blood flow at the apex of the tooth. Obliterating the blood flow that induces vascular stasis can lead to hypoxia or ischemia (9). Therefore, overwhelming the pulp’s defensive

response by bacteria toxin will cease blood circulation to the injured pulp leading to the development of necrosis (18).

The risk of pulp necrosis has been reported to be high in laterally luxated injured tooth and concomitant crown fractures (19). Contrary to the case presented in this study, pulp necrosis developed without compromising the integrity of the crown. The development of pulp necrosis is affected by the age of the child at the time of injury (16) while the repositioning procedure contributes to the incidence of pulp necrosis (2), as presented in this case.

The coronal grey discoloration was hypothesised to occur due to blood that was forced into the dentinal tubules (20, 21) or attributed to the diffusion of blood pigments into the dentinal tubules (22, 23). The other theory was that

the dark discolouration was a result of a surface film (of iron) formation on the dentin (24). A study conducted by Cardoso et al. reported that traumatised primary teeth with crown discolouration had a fivefold tendency of exhibiting pulp necrosis than teeth without crown discolouration (25).

Since long term infection can induce the formation of periapical inflammation leading to permanent damage to the tooth germ (26), pulpectomy is the recommended treatment option for this patient according to AAPD guidelines. However, the patient was uncooperative with the procedure. It was then changed to LSTR procedure for one session, which was favourable for both the patient and parents. This technique was recently included in the 2021 AAPD Guidelines as an alternative treatment option for non-vital primary teeth. It is similar to a pulpotomy procedure in which debriding was performed on the pulp chamber of chronically infected primary teeth. In addition, a combination of antibiotics such as ciprofloxacin, metronidazole, and minocycline, was placed near the root orifice without preparing the radicular portion (27). The main concern with using minocycline is teeth discolouration (11). Hence, amoxicillin was used to reduce the severity of tooth discolouration (28). Any history of antibiotic allergy reported by the patient should be noted and avoided necessarily.

As this procedure does not require any mechanical preparations, it is painless, time-saving, and less of a burden to patients both physically and psychologically (29). This novel approach could eliminate the need for unnecessary general anaesthesia to perform a pulpectomy procedure on one tooth. Other than that, the importance of a follow-up regime until the eruption of the permanent teeth should be highlighted in this case.

Conclusion

The recommended treatment for lateral luxation injury in primary teeth is self-repositioning, repositioning with or without splinting, endodontic treatment when required, or extraction. Successful treatment is influenced by the child's age, cooperation, the severity of the injury, the direction of luxation, and time-lapse between the trauma and seeking dental care. Immediate care with appropriate treatment and follow-up is crucial to minimise the risk of short- and long-term unfavourable outcomes. Coronal discolouration with the presence of a sinus tract is one of the predictors of pulp necrosis following dental injuries. LSTR therapies have the potential to be used as an effective alternative option in the endodontic treatment of primary teeth, especially in uncooperative children.

Competing interests

The authors declare that they have no competing interests.

Consent

Written informed consent was obtained from the parents for the publication of this case report.

Financial support

This research did not receive any funding from public, commercial, or non-profit agencies.

References

1. DiAngelis AJ, Andreasen JO, Ebeleseder KA, Kenny DJ, Trope M, Sigurdsson A, *et al.* International Association of Dental Traumatology guidelines for the management of traumatic dental injuries: 1. Fractures and luxations of permanent teeth. *Dent Traumatol.* 2012;28(1):2-12.
2. Takahashi K, Faria IC, Neves NO, Montano SB, Araujo HC. Traumatic dental injuries in young children. *Arch Heal Investig.* 2019;8(3):113-8.
3. Ritwik P, Massey C, Hagan J. Epidemiology and outcomes of dental trauma cases from an urban pediatric emergency department. *Dent Traumatol.* 2015;31(2):97-102.
4. Arikan V, Sari S, Sonmez H. The prevalence and treatment outcomes of primary tooth injuries. *Eur J Dent.* 2010;4(4):447-53.
5. Cully JL, Zeeb K, Sahay RD, Gosnell E, Morris H, Thikkurissy S. Prevalence of primary teeth injuries presenting to a pediatric emergency department. *Pediatr Dent.* 2019;41(2):136-9.
6. Malmgren B, Andreasen JO, Flores MT, Robertson A, DiAngelis AJ, Andersson L, *et al.* Guidelines for the management of traumatic dental injuries: 3. Injuries in the primary dentition. *Pediatr Dent.* 2016;38:377-85.
7. Day PF, Flores MT, O'Connell AC, Abbott P V., Tsilingaridis G, Fouad AF, *et al.* International Association of Dental Traumatology guidelines for the management of traumatic dental injuries: 3. Injuries in the primary dentition. *Dent Traumatol.* 2020;36:343-59.
8. Campbell KM, Casas MJ, Kenny DJ. Ankylosis of traumatized permanent incisors: pathogenesis and current approaches to diagnosis and management. *J Can Dent Assoc (Tor).* 2005;71(10):763-8.
9. Yu CY, Abbott P V. Responses of the pulp, periradicular and soft tissues following trauma to the permanent teeth. *Aust Dent J.* 2016;61:39-58.
10. American Academy of Paediatric Dentistry. Pulp therapy for primary and immature permanent tooth. *The Reference Manual of Paediatric Dentistry.* Chicago, Ill: American Academy of Pediatric Dentistry; 2021:399-407.
11. Takushige T, Hataoka H, Ando M, Hoshino E. Endodontic retreatment using 3Mix-MP without removal of previous root canal obturation. *J LSTR Ther.* 2009;8:3-7.
12. Takushige T, Cruz EV, Asgor Moral A, Hoshino E. Endodontic treatment of primary teeth using a combination of antibiotic drugs. *Int Endod J.* 2004;37:132-8.
13. Lauridsen E, Hermann NV, Gerds TA, Kreiborg S, Andreasen JO. Pattern of traumatic dental injuries in

- the permanent dentition among children, adolescents, and adults. *Dent Traumatol.* 2012;28(5):358-63.
14. Andreasen JO, Andreasen FM, Mejàre I, Cvek M. Healing of 400 intra-alveolar root fractures. 2. Effect of treatment factors such as treatment delay, repositioning, splinting type and period and antibiotics. *Dent Traumatol.* 2004;20(4):203-11.
 15. Lauridsen E, Blanche P, Amaloo C, Andreasen JO. The risk of healing complications in primary teeth with concussion or subluxation injury—A retrospective cohort study. *Dent Traumatol.* 2017;33(5):337-44.
 16. Borum MK, Andreasen JO. Sequelae of trauma to primary maxillary incisors. I. Complications in the primary dentition. *Endod Dent Traumatol.* 1998;14(1):31-44.
 17. Lauridsen E, Hermann NV, Gerds TA, Ahrensburg SS, Kreiborg S, Andreasen JO. Combination injuries 2. The risk of pulp necrosis in permanent teeth with subluxation injuries and concomitant crown fractures. *Dent Traumatol.* 2012;28(5):371-8.
 18. Yu C, Abbott P V. An overview of the dental pulp: its functions and responses to injury. *Aust Dent J.* 2007;52:S4–6.
 19. Lauridsen E, Hermann NV, Gerds TA, Ahrensburg SS, Kreiborg S, Andreasen JO. Combination injuries 1. The risk of pulp necrosis in permanent teeth with concussion injuries and concomitant crown fractures. *Dent Traumatol.* 2012;28(5):364-70.
 20. Levine N. Injury to the primary dentition. *Dent Clin North Am.* 1982;26(3):461-80.
 21. Wong M, Schmidt JC. Vital bleach of hemorrhagic discoloration. *J Endod.* 1991;17(5):242-3.
 22. Schuur A. *Pathology of the Hard Dental Tissues.* 1st Ed. New Jersey, United States: Wiley-Blackwell. 2012.
 23. Diab M, elBadrawy HE. Intrusion injuries of primary incisors. Part III: Effects on the permanent successors. *Quintessence Int.* 2000;31(6):377-84.
 24. Stangel I, Valdes E, Xu J. Absorption of iron by dentin: its role in discoloration. *J Biomed Mater Res.* 1996;31(2):287-92.
 25. Cardoso M, De Carvalho Rocha MJ. Traumatized primary teeth in children assisted at the Federal University of Santa Catarina, Brazil. *Dent Traumatol.* 2002;18(3):129-33.
 26. Lenzi MM, da Silva Fidalgo TK, Luiz RR, Maia LC. Trauma in primary teeth and its effect on the development of permanent successors: a controlled study. *Acta Odontol Scand.* 2019;77(1):76-81.
 27. Nalawade T, Sogi SP, Bhat K. Bactericidal activity of propylene glycol, glycerine, polyethylene glycol 400, and polyethylene glycol 1000 against selected microorganisms. *J Int Soc Prev Community Dent.* 2015;5(2):114.
 28. Thomas MS. Crown discoloration due to the use of triple antibiotic paste as an endodontic intra-canal medicament. *Saudi Endod J.* 2014;4(1):32-5.
 29. Ali M, Moral AA, Quader SA. Evaluation of pain and tenderness in endodontic treatment of deciduous teeth using (LSTR) 3-Mix MP therapy. *Updat Dent Coll J.* 2018;7(2):9-14.